

THE
UNIVERSITY
OF CHICAGO
LIBRARY

The University of Chicago

INTESTINAL OBSTRUCTION
AN EXPERIMENTAL STUDY OF THE INTOXICATION
IN CLOSED INTESTINAL LOOPS

A DISSERTATION
SUBMITTED TO THE FACULTY
OF THE OGDEN GRADUATE SCHOOL OF SCIENCE
IN CANDIDACY FOR THE DEGREE OF
DOCTOR OF PHILOSOPHY

DEPARTMENT OF PHYSIOLOGY

BY
LESTER REYNOLD DRAGSTEDT

Private Edition, Distributed By
THE UNIVERSITY OF CHICAGO LIBRARIES
CHICAGO, ILLINOIS

Reprinted from
THE JOURNAL OF EXPERIMENTAL MEDICINE, Vol. XXV, No. 3
March, 1917

INTESTINAL OBSTRUCTION.

AN EXPERIMENTAL STUDY OF THE INTOXICATION IN CLOSED INTESTINAL LOOPS.

BY LESTER R. DRAGSTEDT, JAMES J. MOORHEAD, M.D., AND
FRED W. BURCKY.

(*From the Hull Physiological Laboratory of the University of Chicago, Chicago.*)

(Received for publication, November 9, 1916.)

The cause of death in acute intestinal obstruction has not been determined. It is generally conceded, however, that a systemic bacterial invasion by the organisms from the obstructed intestine does not occur. As shown by McKenna (1), a bacteremia is only rarely found in clinical cases of death from acute intestinal obstruction. The absence of a systemic bacterial invasion in experimental obstruction has been demonstrated by a number of workers. The theory of a nervous disorder, as a result of anemia of the medullary centers following the loss of fluids in ileus, has received no experimental support. Both the clinical and experimental evidence so far obtained points to a quickly developing and rapidly fatal toxemia.

Hartwell, Hoguet, and Beekman (2) conclude from experiments on dogs that death in experimental intestinal obstruction is due, first, to a dehydration or loss of water from the tissues as a result of the excessive drain into the lumen of the intestine and vomiting, and, second, to the presence of a toxin in the circulating blood. The toxin is believed to be normally present in the lumen of the intestine, and the factor admitting this toxin into the blood is the damage to the intestinal mucosa. The life of the animal after experimental obstruction may be prolonged by the subcutaneous injection of normal saline solution.

Murphy and Brooks (3) conclude from their experiments on dogs with experimental intestinal obstruction, that death is due to toxemia, independent of infection of the peritoneal cavity or the general circulation. The toxin is formed as a result of bacterial growth in the obstructed intestine. It is not absorbed through a normal mucosa, but gains entrance to the blood stream when the mucosa of the intestine has been damaged. They emphasize the significance of the abnormal absorption in the production of the symptoms.

Whipple, Stone, and Bernheim (4) believe that death in these cases of obstruction is due to the absorption directly into the blood of a perverted secretion

of the duodenal or upper jejunal mucosa. They assume a disturbed physiological balance of the mucosa by which abnormal products are formed and secreted into the blood stream. This perverted secretion is a highly toxic substance and they claim that it can be recovered from the lumen of the intestine in cases of obstruction. Some work has been reported on the chemical nature of this toxic substance and attempts have been made to immunize dogs to it.

Draper (5) believes that the cause of death in intestinal obstruction is due to an aberrant activity of the duodenal and probably the pancreatic cells. He appears to have forsaken the view taken by him several years ago of a normal toxic secretion from the duodenal mucosa which is neutralized by the secretions of the intestine lower down.

There has not been a sufficiently thorough investigation of the chemical nature of the toxic substances found in the lumen of the intestine in cases of intestinal obstruction to determine whether they are essentially different from the toxic substances shown by Roger and Garnier (6) to be present in the lumen of the normal stomach and intestine. We should expect to find materials, in such a mixture of food substances and bacterial end-products as exists in the normal alimentary tract, which are toxic when injected into the blood stream. That the substances from the intestine in cases of obstruction are apparently more toxic than the normal contents of the intestine is not surprising. The accumulation of food products and secretions and the unrestricted activity of the intestinal bacteria might easily explain the increase in toxicity. Moreover, an intravenous injection of substances from an obstructed intestine producing toxic symptoms does not indicate that such a procedure occurs in cases of acute obstruction in which these toxic materials are separated from the blood by a layer of living cells. It is the function of the cells to change the substances in the lumen of the intestine to substances which can enter the blood stream without harm to the organism. The normal physiological function of the cells of the intestinal mucosa is both secretory and absorptive. Any pathological alteration (anemia through disturbance to the blood supply, traumatism, etc.) or intoxication of these glandular structures would, we should expect, lead to a depression and not a stimulation of their activity. We should expect a decrease and not a sudden increase in the absorptive properties of these cells under conditions such as exist in intestinal obstruction. Indeed, it has been shown by Braun

and Boruttau (7) and others that there is in reality a decrease in absorption from the intestinal lumen in cases of acute experimental obstruction. If, as maintained by some of the workers, the toxemia of obstruction is due to the absorption of toxic substances normally present in the intestine, made possible through the injury to the intestinal mucosa, this toxemia should be manifest in other inflammatory conditions of the intestine such as are present in ulcer, typhoid fever, amebic dysentery, etc., where there is extensive destruction of the mucosa.

The theory of a non-bacterial or physiological formation of the toxic substances found in the intestine in cases of acute obstruction, as advanced by Whipple and his associates and in a modified form by Draper, is not conclusive. The theory that under conditions of obstruction the normal physiology of the mucosa cells is so changed that they secrete a powerful toxin into the circulation is not probable. Especially is this so since cases of congenital atresia of the duodenum and other parts of the intestine are not rare. The infant shows no signs of toxemia or untoward symptoms until bacteria get into the alimentary tract after birth. The secretions of the intestinal glands begin early in intra-uterine life, and if there is anything significant in obstruction alone in stimulating a toxic secretion, such a secretion and toxemia would be manifest before birth. This does not exclude the factor of bacteria and food coupled with the anatomical condition of obstruction as important in the stimulation to a perverted secretion. From the work of others and from experiments to be reported here, this explanation seems unlikely.

To summarize briefly, death in acute intestinal obstruction is held to be due to a toxemia. That there are toxic substances formed in the intestine is established. That the substances found in the lumen of the intestine in obstruction are more toxic than the substances normally present is indicated. The presence of toxic substances in the blood in obstruction has not been shown. The relation of the toxic substances in the intestine in experimental obstruction to the symptoms, and the factors involved in the production and absorption of these toxic substances are the fundamental questions in the problem of intestinal obstruction which remain unsettled.

All the experiments were done under complete ether anesthesia and with careful aseptic technique. In no case was there an extensive wound infection, and in no instance was there a peritonitis from the operation itself.

Isolated Closed Loops of the First Part of the Jejunum.

Experiments were performed on five dogs, but the results were so uniform that only one protocol will be given.

Dog 1.—May 12, 1916. An isolated closed loop, about 12 cm. in length, of the first part of the jejunum (Text-fig. 1) was made, the continuity of the intestine reestablished by end to end suture, and the ends of the isolated loop were carefully infolded and closed. Care was taken not to injure the blood supply to the isolated loop.

May 13. Dog recovered from the immediate effects of the operation; appeared lively.

May 14. Dog weak; vomited on drinking water.

May 15. Found dead and cold in the cage.

Autopsy.—Performed at once. There was a considerable amount of fluid in the abdominal cavity, and the peritoneum was markedly injected, with evidence of a general peritonitis. The loop was greatly distended and perforated in the center, opposite the mesentery. Aside from the region of the perforation, the mucosa was practically normal. Microscopic examination showed merely a slight round cell proliferation and desquamation of some of the surface cells. The lungs, liver, and kidneys showed no change. There was a slight cloudy swelling in the spleen.

All the dogs in this series died within 96 hours and all showed a perforation of the closed loop and a general peritonitis. The perforation was evidently primarily caused by the accumulation of fluids in the closed loop. The distention was probably sufficient to shut off the blood supply to a portion of the mucosa which, becoming necrotic, rapidly gave way. We believe that death in these cases is due to the perforation and the sudden liberation of bacteria and their toxic end-products into the abdominal cavity where they are rapidly absorbed. The effects of the perforation cannot be essentially different from those in perforated ulcers and there seems to be no reason to believe that the small area of necrosis in these cases plus bacteria could give rise to a sufficient amount of toxic substances rapidly

enough to produce the symptoms observed. The inflammatory condition of the intestine adjacent to the perforation is not more marked than that found in any acute enteritis.

Isolated Closed Loops of the Lower Intestine.

Dog 2.—Apr. 6, 1916. An isolated loop, 12 cm. in length, of the lower part of the jejunum was made, the intestinal canal reestablished by end to end suture, and the ends of the isolated loop were carefully infolded and closed. The blood supply to the loop was not damaged.

Apr. 7. Dog lively.

Apr. 9. Dog appeared toxic; vomited on drinking water.

Apr. 10. Found dead and cold in cage.

Autopsy.—Performed at once. The abdominal organs were normal except for the loop which was markedly distended and perforated causing a general peritonitis.

Dog 3.—Apr. 20, 1916. An isolated loop of the lower end of the ileum about 12 cm. in length was made, the intestinal canal reestablished by end to end suture, and the ends of the isolated loop were carefully infolded and closed. The blood supply to the loop was not damaged.

Apr. 21. Dog lively.

Apr. 25. Dog found dead and cold in cage.

Autopsy.—Performed at once. The closed loop was greatly distended and perforated causing a general peritonitis.

Dog 4.—May 25, 1916. An isolated loop, 12 cm. in length, of the transverse colon was made, the intestinal canal reestablished by end to end suture, and the ends of the isolated loop were carefully infolded and closed. The blood supply to the loop was not damaged.

May 26. Dog lively.

May 28. Dog able to eat and drink; appeared normal.

June 4. Dog died of distemper.

Autopsy.—Perforation of the closed loop which had been sealed by the omentum. There was a localized collection of pus about the perforation, but no general peritonitis.

In two cases isolated closed loops of the intestine in the region of the lower jejunum were made, the dogs living 4 and 5 days respectively. Death in each instance was caused by a perforation of the closed loop and the liberation of the toxic substances into the abdominal cavity. The dog with the closed loop of the ileum lived 5 days, death being due to the perforation peritonitis. Dogs with closed loops of the colon may live for weeks with no pathological symptoms.

Isolated Closed Loops of the Duodenum.

Dog 5.—July 6, 1916. An isolated loop of the duodenum, about 12 cm. in length, below the lower pancreatic duct was made, the continuity of the duodenum reestablished by end to end suture, and the ends of the isolated loop were carefully infolded and closed, great care being taken not to injure the large duodenal vein which at this point runs parallel to the intestine.

July 7. Dog highly toxic; refused water; lay quietly in corner of cage.

July 8. Dog died 48 hours after the operation.

Autopsy.—Performed at once. No peritonitis. The abdominal organs were normal except the closed loop. The loop was markedly distended and gangrenous but not perforated. The fluid in the loop was of the consistency of thick soup, bloody, and very offensive. It contained great numbers of bacilli and cocci. The mucosa of the loop was necrotic, coming away from the wall of the intestine as a brick red powder.

Six dogs were operated upon as described above and all died within 50 hours. At autopsy there was a perforation of the loop and general peritonitis in two animals, but in the remaining four the loops were distended but intact. In every instance the loop was black and gangrenous as compared with the remainder of the intestine. The mucosa always showed the same change and was markedly necrotic. The lungs, liver, and spleen were practically normal.

Closed Pavlov Pouch.

Dog 6.—Feb. 29, 1916. An operation for making a regular Pavlov pouch was performed, but instead of making a fistula, the small stomach was entirely closed (Text-fig. 2).

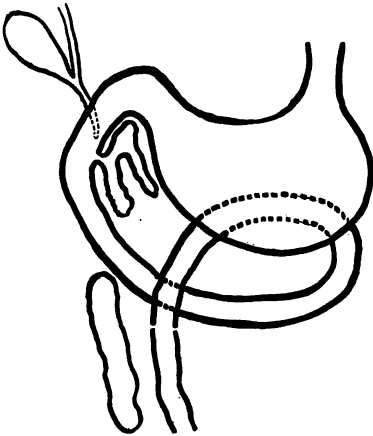
Mar. 1. Dog lively; no signs of toxemia.

Mar. 2. Dog died 54 hours after the operation.

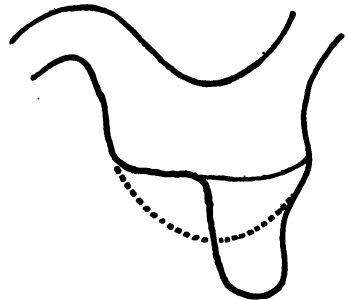
Autopsy.—Performed at once. The small stomach or pouch was greatly distended and perforated opposite the sutures. General peritonitis. The mucosa of the stomach and duodenum was not injected.

The experiments described in the above four groups are in part a duplication of experiments reported by other workers. Our purpose was to corroborate their findings and to establish a basis for our later experiments. They bring out the following facts: (1) Dogs with short closed isolated loops of the intestine die, those with loops in the upper part more rapidly than those with loops lower down. (2) There is no excessive vomiting of fluids with a resultant dehydration

of body tissues. (3) Dogs with closed isolated loops of the jejunum and ileum always show a perforation of the loop and general peritonitis at autopsy. Aside from the perforation the mucosa is not markedly changed. (4) Dogs with closed isolated loops of the duodenum die more quickly than dogs with closed loops in any other part of the intestine. At autopsy there may be an intact closed loop and no signs of peritonitis. In all cases where death occurs rapidly (within 48 hours), the mucosa of the closed loops is necrotic. In these cases the loops are distended with a fluid which contains great numbers of putrefactive bacteria.



TEXT-FIG. 1. Isolated closed loop of the first part of the jejunum.



TEXT-FIG. 2. Closed Pavlov pouch.

Isolated Closed Loops of the Upper Part of the Jejunum, Previously Washed with Sterile Water and Ether.

Isolated loops of the jejunum just below the duodenojejunal flexure were made (Text-fig. 1) and the continuity of the intestine was re-established by end to end suture. The isolated loops were then carefully washed with about 2 liters of sterile water and then with 2 liters of ether. A spray was used for this work and the fluids were introduced at sufficient pressure to distend the loops, thus affording a thorough washing of the mucosa. Following the washing, the ends of the loop were carefully wiped, infolded, and closed. Twenty-

five dogs were operated on in this manner and the postoperative course varied greatly. Sixteen of the dogs died after an interval varying from 2 to 6 days. In all the sixteen dogs there was a perforation of the loop with a resulting general peritonitis. That there had been a great distention of the closed loop before perforation was shown by the great thinness of the wall in places. The course in these dogs was no different from that in dogs in which the loops were not washed. The remaining nine dogs, which were operated on as above, and in which the isolated loops were first carefully washed with sterile water and ether, quickly recovered from the immediate effects of the operation and never showed any subsequent ill effects. Some of the dogs were later operated on and the loops examined. Others were not interfered with following the operation. They are still alive (5 months) and will probably continue to live indefinitely. Dogs which were opened from 2 to 3 weeks following the operation showed a fairly uniform picture. In nearly all, the ends of the loop remained tightly closed and aside from a slight distention the loops appeared practically normal. The fluid in the loops was gray in color and of the consistency of thick soup. Bacteriological examination showed the presence of *Bacillus coli* and a small coccus in most instances.

Merely washing the isolated loops with sterile water before closure does not suffice to save the animal from death within a week, although it prolongs life somewhat. There are at least four explanations of the absence of symptoms and death in the case of the ether washing of the loop. (1) The specific bacterium causing the elaboration of the toxic product in the closed loop may have been removed. The bactericidal property of the ether itself may have been sufficient to destroy the bacteria, or the hyperemia incited by the ether as an irritant may have been instrumental in aiding phagocytosis. (2) The substrate upon which bacteria act to produce the toxic product may have been washed out by the ether. (3) The secretory activity of the cells may have been sufficiently depressed to prevent the accumulation of enough fluids to distend the intestine to the point of rupture. The recovery of the cells from the effects of the anesthetic was probably sufficiently gradual to permit the establishment of an equilibrium between the amount of secretion into the lumen of the in-

testine and the amount of absorption. (4) The absorptive properties of the cells of the washed loops may have been increased through the removal of the lipid envelopes of the cells by the ether.

Isolated Closed Loop of the Jejunum, Previously Washed with Sterile Water and Ether.

Dog 7.—June 29, 1916. An isolated loop of the first part of the jejunum about 12 cm. in length was made, carefully washed with 2 liters of sterile water and 2 liters of ether, the ends were infolded and closed, and the continuity of the intestine was reestablished by end to end suture.

June 30. Dog lively.

July 1. No signs of toxemia.

July 4. Dog able to eat and drink; appeared normal.

July 8. Laparotomy and examination of the loop. The ends of the loop remained tightly closed. There was a large perforation 2 by 4 cm. in the middle of the loop opposite the mesentery. No evidence of peritonitis. The peritoneum was smooth and shining. There were a few adhesions about the end to end joint in the intestine. The perforation was closed by double rows of Lembert sutures and the loop dropped back into the abdomen. The blood supply to the returned loop was good.

July 10. Dog weak; lay in corner of the cage.

July 12. Dog well and lively.

July 20. Dog apparently in good condition; etherized.

Autopsy.—The abdominal cavity was normal except for the loop, which was entirely surrounded by omentum. It was tightly closed and moderately distended. The fluid in the loop was thick and yellow in color. The mucosa of the loop was normal on gross and microscopic examination. Cultures taken from the loop fluid remained sterile.

The subsequent perforation of the isolated closed loop, in this experiment, without symptoms of intoxication or evidence of peritonitis indicates that the fluids responsible for the distention of the loop and consequent perforation are not necessarily formed as a result of bacterial activity. They are probably non-toxic secretions from the intestinal cells, the activity of which could not have been permanently inhibited by the ether. The lumen of the intestine must have been practically sterilized by the washings or else the perforation must have occurred before there was any marked proliferation of the bacteria and elaboration of their toxic end-products. In this instance the formation of the closed loop did not suffice so to alter the normal

function of the jejunal cells as to stimulate them to the formation of a toxic secretion, either into the blood stream or into the lumen of the intestine. The perforation of the loop allowed free access of the bactericidal abdominal juices into the lumen of the isolated loop and consequent sterilization, as shown by the negative cultures taken on July 20. This experiment demonstrates that an aseptic isolated closed loop of the upper jejunum is not incompatible with life.

Isolated Closed Aseptic Loop of the Lower Jejunum, in Which the Blood Supply Was Occluded with No Untoward Symptoms.

Dog 8.—Apr. 19, 1916. An isolated closed loop of the lower part of the jejunum about 12 cm. in length was made, having been previously washed with sterile water and ether, the ends were infolded and closed, and the continuity of the intestine was reestablished by end to end suture. The blood supply to the loop was not damaged.

Apr. 21. Dog made a good recovery; no toxic symptoms.

July 3. Dog in good condition; laparotomy and examination of the loop. The isolated loop was open at one end, and the secretions of the loop had free drainage into the abdominal cavity. The loop was normal in appearance. There was no evidence of peritonitis, although a few cheesy white flakes could be found in the mesentery. The end of the loop was closed and the entire blood supply to the loop was occluded by double ligatures around the vessels in the mesentery. Cultures taken of the contents of the loop before closure remained sterile.

July 5. Dog recovered from the operation and showed no toxic symptoms.

Oct. 10. Dog was in good condition and had never shown any ill effects from the operation. Laparotomy and examination of the abdominal contents were done. The intestinal loop had entirely disappeared and the only trace of it that could be found was a bit of fibrous connective tissue in the mesentery in the region of the end to end joint in the intestine.

This experiment confirms the results obtained with Dog 7. The washings probably reduced the bacterial content of the intestine to such an extent that the bactericidal juices of the abdomen were able to cope with the remaining bacteria. It shows that isolated intestinal loops of the lower jejunum can be effectually sterilized by this method and also that isolated closed aseptic loops in the region of the lower jejunum are not incompatible with life. It also establishes the fact that anemic necrosis of the intestine following occlusion of the blood supply produces no toxic symptoms when bacteria are excluded.

There is thus a simple aseptic infarct of the intestine. Evidently then the toxemia of intestinal obstruction cannot be due to circulatory changes in the intestine in the absence of bacteria.

Isolated Closed Loop of the Jejunum. Recovery. Death on Subsequent Occlusion of the Blood Supply.

Dog 9.—June 30, 1916. An isolated loop of the first part of the jejunum about 12 cm. in length was made, washed with sterile water and ether, the ends were infolded and closed, and the continuity of the intestine was reestablished by end to end suture.

July 2. Dog recovered from operation; showed no toxic symptoms.

July 10. Dog in perfect health; laparotomy and examination of the loop. There were no signs of peritonitis. The loop was markedly distended but not perforated. The walls of the loop were normal in appearance, thickness, and color, and the blood supply was good. The blood supply was entirely occluded by double ligatures about the vessels in the mesentery and the loop dropped back into the abdomen.

July 11. 24 hours after the operation the dog was found dead.

Autopsy.—Performed at once. The abdomen was distended with gas and bloody, offensive fluid. The loop was entirely disintegrated and separated from the mesenteric stump. Cultures taken from the abdominal cavity showed *B. coli*.

It will be noted that washing the isolated loops of the intestine does not in itself completely remove all the organisms present. It was the subsequent entrance of the bactericidal abdominal juices in the ruptured loops that completed the sterilization in these cases. *Bacillus coli* and cocci were found in the closed loops that were later examined. In this experiment, then, there were probably a great number of bacteria and their end-products in the lumen of the loop. It has been shown that bacteria proliferate rapidly in these closed loops where the conditions for their growth are favorable. However, the mucosa of the intestine is able to prevent the entrance of bacteria or their toxic products into the blood in sufficient amounts to produce symptoms. This is a normal function of the mucosa of the intestine and is evidently not changed by the condition present in a closed isolated loop. The secretion into the lumen of the loop is practically balanced by the absorption from the intestine so that whatever distension occurs is gradual enough for the blood supply to accommodate itself. Thus a condition of anemia and necrosis of

any part of the loop is prevented. However, when the entire blood supply was suddenly occluded, the loop became at once necrotic, and this necrotic tissue plus the enclosed intestinal bacteria resulted in the formation of toxic products, which when liberated into the abdominal cavity and absorbed caused death. Whether the mere liberation of the contents of the loop without necrosis of the tissue would have caused death we do not know. However, from the fact that the liberation of the contents from a washed loop caused no symptoms, it would seem that this tissue necrosis is an important factor.

Isolated Closed Loops of the Lower Duodenum, Previously Washed with Sterile Water and Ether.

Seven dogs were operated on as in Text-fig. 3, the isolated loop of the lower duodenum was carefully washed with sterile water and ether, and the ends were infolded and closed. All the dogs died within 72 hours. There was no marked difference in the post-operative course of these dogs and the dogs in which the closed loops of the duodenum had not been previously washed. All made an uneventful recovery from the immediate effects of the operation and showed nothing abnormal for the first 12 hours. Then symptoms of toxemia, extreme muscular weakness, vomiting, diarrhea, and muscular tremors, appeared, followed by prostration and death. At autopsy the isolated loops were greatly distended and black or covered with purple blotches. In four animals there was a perforation with signs of a beginning general peritonitis. In three, however, there was no perforation and no signs of peritonitis were present. The loops were all distended and black in appearance. In every instance they were filled with a foul smelling bloody fluid. This fluid was found to contain large numbers of *Bacillus coli*, cocci, and other bacilli. In all the dogs the mucosa was necrotic and in some it appeared as a red granular powder.

There are two probable factors accounting for our failure to keep the dogs with the washed closed loops of the duodenum alive. In the first place the upper part of the intestine is mainly secretory and very slightly absorptive in function. Consequently there is little chance to establish an equilibrium between secretion into the intestine

and absorption from it. Second, the arrangement of the blood supply to the duodenum is different from that in any other part of the digestive tract. The vessels supplying the duodenum run parallel to the lumen of the intestine. Any slight distention of the duodenum may easily occlude these vessels and thus shut off the circulation to the entire duodenum. We attribute the failure to keep dogs with closed loops in this region alive as due to these two factors and not to anything peculiar in the quality of secretion of the glands in the duodenum or in the bacterial flora.

Experiments to Determine the Part of Ether in the Washed Isolated Loops.

Dog 10.—May 17, 1916. An isolated loop of the first part of the jejunum about 12 cm. in length was made, washed with sterile water, the ends were infolded and closed, the continuity of the jejunum was reestablished by end to end suture, and the loop filled with ether and dropped back into the abdominal cavity.

May 19. Dog found dead.

Autopsy.—Performed at once. There was a perforation of the closed loop, and signs of a beginning general peritonitis were present. The mucosa aside from the region of the perforation was normal.

Two dogs were operated on in this manner and both died within 48 hours. The experiment was undertaken to find out if the function of the ether was to remove a substrate upon which bacteria might act to produce a toxic product. If the ether was left in the loop, its germicidal and its anesthetic effects on the cells would be the same, but no substrate would be removed. However, the experiment is subject to the criticism that the ether enclosed in the loop when warmed to the temperature of the body might exert sufficient pressure to rupture the loop and liberate the contents.

Isolated Closed Loops of the Jejunum and Colon, Previously Washed with Sterile Water and 70 Per Cent Alcohol.

Closed loops of the upper part of the jejunum were made in seven dogs, the loops being carefully washed with sterile water and 70 per cent alcohol before closure. Of these seven dogs, five died within 4 days with perforation of the loop and general peritonitis. One died in 5 days with a peritonitis from a leak in the joint. The iso-

lated loop in this animal was distended but intact. Cultures taken from the loop fluid showed *Bacillus coli*, a streptococcus, and *Bacillus subtilis*. One of the dogs lived 18 days, but died with a peritonitis from perforation of the closed loop.

Isolated closed loops of the transverse colon, washed with sterile water and 70 per cent alcohol, were made in three dogs. One dog died after 3 days with a perforation of the loop and resulting general peritonitis. The other two showed no untoward symptoms and were later opened and the loops examined. In one of the dogs opened 19 days after the first operation, the closed loop was found intact but somewhat distended. The other dog was opened after 28 days and the loop removed. Here also the loop was distended and intact. In both these animals the fluid in the closed loops was of a dirty chocolate color, foul odor, and contained great numbers of bacteria.

It will be seen that dogs with alcohol-washed loops live longer than dogs with simple closed loops or dogs in which the loops have been washed with sterile water before closure. It is probable that alcohol acts in much the same manner as ether.

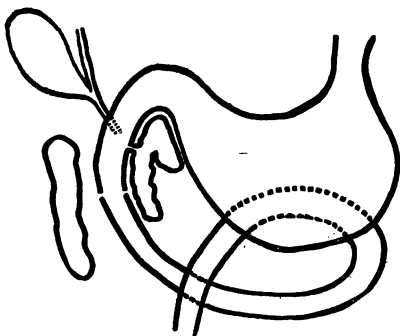
Isolated Loops of the Upper Jejunum, Previously Washed with Sterile Water and Lysol Solution. Ends Closed.

A 2 per cent solution of lysol was used and experiments were performed on two dogs. Both died within 48 hours with a perforation of the closed loop and a general peritonitis. In both the mucosa of the loop was necrotic and separated from the muscularis.

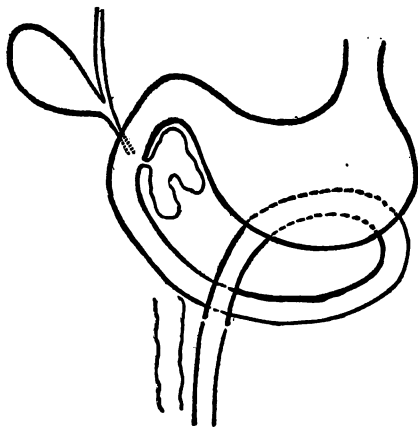
Isolated Loops of the Jejunum, Previously Washed with Sterile Water, Dropped Back into the Abdomen with Both Ends Open.

The perforation of closed loops of the jejunum and the non-appearance of peritonitis or toxic symptoms in some of the previous experiments, led us to attempt experiments of this kind. Four dogs were operated on as in Text-fig. 4, the isolated loops were made in the usual manner but were dropped back into the abdomen with both ends open. All the dogs made uneventful recoveries from the operation and never showed any toxic symptoms. Two of the dogs were

opened 3 weeks after the first operation and the loops examined. The ends remained open although the loops were surrounded by numerous adhesions. There was some light yellow fluid in the abdominal cavity and a few white cheesy flakes in the mesentery. The other two dogs were opened 4 and 5 weeks respectively after the first operation. The loops were buried in adhesions and both ends tightly closed. They were moderately distended. Pressure on the loops



TEXT-FIG. 3. Closed loop of the duodenum.



TEXT-FIG. 4. Open loop of the first part of the jejunum.

caused no escape of fluid from the sealed ends. The fluid in these loops was yellow and quite thick. Cultures on physiological blood agar were negative.

Isolated Loops of the Duodenum Dropped Back into the Abdominal Cavity with Both Ends Open.

Dog 11.—July 20, 1916. An isolated loop of the duodenum about 10 cm. in length below the lower pancreatic duct (Text-fig. 5) was made, the continuity of the duodenum reestablished by end to end suture around the loop, and the loop dropped back into the abdomen without washing and with both ends open.

July 23. Dog recovered from operation; showed no signs of toxemia.

Aug. 10. Dog in perfect health; nutrition has not suffered since operation; laparotomy and examination of the loop. Both ends of the loop were tightly sealed by adhesions. The loop was distended, but pressure applied to it did

not cause any fluid to escape from the ends. It was dropped back and the abdomen closed.

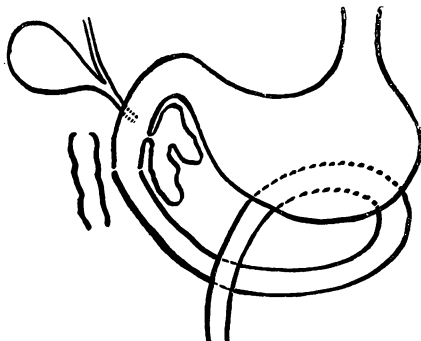
Aug. 11. Dog recovered from the operation.

Aug. 15. Dog apparently in perfect health no signs of intoxication since operation.

Aug. 20. Dog etherized.

Autopsy.—Performed at once. There was some thin yellow fluid and a few flakes of fibrin were found in the abdominal cavity. The isolated loop was closed and wrapped in dense adhesions. Thick gray fluid was present in the lumen. The mucosa was normal on gross and microscopic examination. No cultures were made of the fluid in the loop.

Six dogs were operated on in the above manner. Three died within 5 days of a general peritonitis. The remaining three showed no



TEXT-FIG. 5. Open loop of the duodenum.

untoward symptoms whatever after the operation. One was opened after 16 days, the isolated loop inspected, and the ends were closed. At operation the loop appeared normal and the blood supply was good. Following the second operation the dog developed a hernia and was etherized 3 days later. The other two dogs were opened 20 and 30 days respectively after the first operation. In both these animals the loops were tightly closed by adhesions and were distended with a thick yellow fluid. Cultures made in one case were negative. In both instances the muscularis and mucosa were normal on gross and microscopic examination.

The experiments with the open loops of the jejunum and duodenum show conclusively that the secretions of the jejunum and duodenum are not toxic enough to induce symptoms in dogs when allowed to

flow into the abdominal cavity. Whether these secretions are toxic when injected into the blood stream, we do not know. All the normal stimuli to the secretion of the glands of the intestinal mucosa are not present, but the secretion goes on, and it is probable that this secretion is qualitatively the same in the isolated open loops as in the intact intestine. There has been no damage to the secreting cells either through injury to the cells themselves directly (trauma in washing) or to their blood supply. The experiments also show that the theory of Draper of a normal toxic secretion of the mucosa of the duodenum which is neutralized by the jejunal juices is untenable. The juices of the open loops of the duodenum are absorbed directly from the abdominal cavity and do not come in contact with the mucosa of the jejunum and ileum. Also there is no perverted secretion or aberrant activity on the part of the cells of the duodenal mucosa when the factor of the bacteria of the intestine is excluded and when the blood supply is not occluded by a too rapid distention of the loops.

DISCUSSION.

It has been demonstrated that death in experimental intestinal obstruction may occur in the absence of a systemic bacterial invasion or of peritonitis. It is probable that the symptoms and death are due to a rapidly developing toxemia, although toxic substances have not been demonstrated in the blood in cases of experimental obstruction. As there was no excessive vomiting of fluids in our experiments the theory of dehydration of the body tissues receives no support. We were able to keep alive animals with closed loops of the duodenum and upper jejunum where bacteria had been previously removed from the loop by free drainage into the abdominal cavity. Inasmuch as the mucosa of these loops was not injured in any way, the theory of a perverted secretion of the mucosa cells induced by the condition of obstruction present in closed duodenal loops, as advocated by Whipple, appears untenable, as is also the theory of Draper of an aberrant activity of the cells of the duodenum and the pancreas. The early theory of Draper that the toxemia in obstruction was due to the absorption of toxic secretions of the duodenum which were normally neutralized by the juices of the intestine lower

down, is disproved by the experiments with the open duodenal and jejunal loops in which these unneutralized secretions pass directly into the abdominal cavity and are absorbed, without the production of toxic symptoms.

We were also able to keep alive dogs with closed loops of the intestine (loops washed with sterile water and ether) containing bacteria, but in which the blood supply had not been damaged by distention. Thus, it is probable that bacteria alone or in connection with the contents of the lumen of the intestine, do not give rise to the toxemia of obstruction, when they are separated from the blood by the cells of the intestinal mucosa. However, a combination of these two factors (necrotic tissue plus putrefactive intestinal bacteria) rapidly gives rise to fatal toxemia. It is probable that the death in the experiments with the unwashed isolated intestinal loops is identical with that following gangrene of the intestine. The fatal toxins are the result of the action of the putrefactive organisms on necrotic tissue. That dogs with closed loops of the duodenum die sooner than dogs with closed loops lower down in the intestine may be due to the fact that the duodenal loop becomes entirely necrotic on distention by reason of the arrangement of the blood supply while in the cases of the loops of the remainder of the intestine only the tissue in the immediate vicinity of the perforation becomes necrotic. Death in the latter cases may be caused by the peritonitis resulting from the perforation. The area of necrosis or gangrene in the lower intestine is usually so small that it is probable that sufficient toxic products to account for the symptoms could not be formed.

Just how far the conditions present in closed isolated unwashed loops of the intestine resemble those found in clinical obstruction is problematic. We believe that the symptoms and pathology of these simple closed loops resemble cases of acute obstruction in man in which there is an accompanying occlusion of the blood supply to a part of the intestine (volvulus, strangulated hernia, etc.). The toxemia resulting from closed intestinal loops is not similar to the toxemia resulting simply from a delay in the passage of food in the intestine and in which there is no disturbance of blood supply or injury to the tissue.

CONCLUSIONS.

1. Closed intestinal loops in which bacteria are first removed are compatible with life.
2. Closed intestinal loops in which bacteria are present but in which tissue necrosis is prevented, are compatible with life.
3. Closed aseptic intestinal loops in which the blood supply is completely occluded are compatible with life.
4. The normal secretions and bacterial products of the duodenum and jejunum are not sufficiently toxic to produce any symptoms when allowed to drain into the abdominal cavity.
5. Our results do not support the theory of Draper of a normal toxic secretion of the duodenal mucosa, neutralized by the jejunal mucosa, or the perverted secretion theory of Whipple.
6. Bacterial activity plus necrotic tissue, or the absorption of toxic products resulting from the action of putrefactive bacteria on necrotic tissue is the important factor in the rapid death in simple closed intestinal loops.

The authors wish to express their thanks to Dr. A. J. Carlson for suggestions and criticism during the course of the experiments and other assistance, and to Dr. C. S. Chase for facilities in the preparation of the paper.

BIBLIOGRAPHY.

1. McKenna, C. H., *Surg., Gynec. and Obst.*, 1913, xvii, 674.
2. Hartwell, J. A., and Hogue, J. P., *Am. J. Med. Sc.*, 1912, cxliii, 357; *J. Am. Med. Assn.*, 1912, lix, 821. Hartwell, J. A., *J. Exp. Med.*, 1913, xviii, 139. Hartwell, J. A., Hogue, J. P., and Beekman, F., *Arch. Int. Med.*, 1914, xiii, 701.
3. Murphy, F. T., and Brooks, B., *Arch. Int. Med.*, 1915, xv, 392.
4. Whipple, G. H., *J. Exp. Med.*, 1912, xv, 259. Whipple, G. H., Stone, H. B., and Bernheim, B. M., *ibid.*, 1913, xvii, 286, 307; 1914, xix, 144, 166.
5. Draper, J. W., *J. Am. Med. Assn.*, 1916, lxxvii, 1080; 1911, lvii, 1338.
6. Roger, G. H., *Rev. sc., Series 5*, 1907, vii, 65; *Presse méd.*, 1911, 1. Roger, H., and Garnier, M., *Rev. méd.*, 1906, xxvi, 609; *Presse méd.*, 1906, 325.
7. Braun, W., and Boruttau, H., *Deutsch. Chir.*, 1908, xcvi, 544.